



## PATIENT

Sebastian Robertson

## SPECIES

Feline

## BREED

DSH

## SEX

MN

## AGE

7yr

## WEIGHT

10.42lb

## INTERPRETED BY

R. McKenzie Daniel,  
DVM, DABVP  
(Canine and Feline)

## IMAGING PERFORMED BY

Amanda Crook

## HOSPITAL NAME

Rivers Edge Pet  
Medical Center

## REFERRING VET

Dr Bridget Hayes

## INVOICE

25040

## DATE

06/08/2026

## PRESENTING CLINICAL SIGNS

Gradual weight loss. Unable to palpate right kidney, left kidney feels large. Moderate muscle wasting. Normothermic.

Current Medications: none

Abnormal PE/Chem/CBC/UA Results: Laboratory Abnormalities (please indicate if WNL): mild anemia, low phos and calcium (corrected calcium normal) Marked hyperglobulinemia = 6.4 g/dL  
Radiographic Findings (if applicable): large left kidney (trace mineralization?), unable to visualize right kidney. No masses seen in abdomen or chest.

## ULTRASONOGRAPHIC EXAMINATION OF THE ABDOMEN

### Urinary System

The urinary bladder, trigone, cystourethral junction, and visible pelvic urethra to a depth of 2 cm exhibited normal thickness and tone. Anechoic urine was present in the lumen with mild non-dependent particulate sediment. The ureteral papillae were normal. The ureters were not visible, which is normal. No evidence of inflammatory or neoplastic changes was noted.

Borderline increased size was present in the left kidney. A normal 1:3 cortex / medulla ratio was maintained. The medulla and cortices were uniform in texture with some increased echogenicity and mild loss of corticomedullary symmetry and definition expected for the age of the patient. No evidence of pelvic dilation was present. Mild medullary to pelvic non-obstructive mineral was present. The left kidney measured 0.45 cm in length.

Subnormal renal size with asymmetrical margination was present in the right kidney. The renal cortex presented uniformly increased in echogenicity with uniform echotexture. The renal cortex appeared to be hypertrophied resulting in an altered cortex: medulla ratio. Indistinct loss of corticomedullary distinction was also present. The renal medullary volume was subjectively reduced. The right kidney measured 2.8 cm in length.

The area of the aortic trifurcation was free of pathology.

### Adrenal Glands

The left adrenal gland was uniform in size and contour with a uniformly hypoechoic parenchyma. The left adrenal gland measured 0.45 cm. The right adrenal gland was uniform in size and contour with a uniformly hypoechoic parenchyma. The right adrenal gland measured 0.47 cm width.

### Spleen

The spleen was normal in size with maintained symmetrical capsule contour. Subtle, multifocal, small to discrete, hypoechoic nodules were present diffusely throughout the parenchyma without associated capsule impingement or distortion. The splenic vasculature at the hilus was normal in volume with no evidence of congestion or thrombosis. The spleen measured 0.9 cm in width at the level of the mid spleen.

### Liver/Gallbladder

The liver was subjectively borderline enlarged in size. The liver parenchyma was uniform and hypoechoic to the spleen with a mild coarse echotexture. Normal vascular volume. The hepatic and



## PATIENT

Sebastian Robertson

portal vasculature were normal in appearance without signs of congestion. The gallbladder was non-distended in size with thin walls and mild non-organized debris. The proximal common bile duct was dilated and mildly tortuous without overt post hepatic obstruction.

## SPECIES

Feline

The stomach presented intact wall layering with a normal wall layer ratio. The lumen of the stomach was empty with no signs of ileus, obstruction or foreign material.

## BREED

DSH

The small intestine presented intact wall layering with 1:3 muscularis/mucosa ratio. The lumen of the small intestine was empty with no signs of mechanical/metabolic ileus, obstruction or foreign material. The small intestinal wall measured 0.24-0.25 cm in width.

## SEX

MN

Normal visible colon wall layers were present with apparent formed feces in lumen.

### *Pancreas*

The pancreas exhibited variable prominent size with capsule asymmetry and non-homogenous subtle hypoechoic parenchyma compared to adjacent omentum.

## AGE

7yr

### *Free Abdomen*

No evidence of peritoneal effusion was present.

Mid to cranial mesenteric lymphadenopathy was present, an example measured 3.1 cm x 0.99 cm.

## WEIGHT

10.42lb

## ULTRASONOGRAPHIC FINDINGS

### Primary

- Sonographically normal gastrointestinal tract
- Prominent non-homogenous subtle hypoechoic pancreas
- Borderline hepatomegaly
- Gallbladder debris with mild non-obstructive proximal common bile duct dilation
- Subtle micronodular spleen - lymphoid hyperplasia, hematopoiesis, potential emerging or occult splenic neoplasia
- Variable mesenteric lymphadenopathy - hyperplasia, lymphadenitis, early neoplasia / metastasis possible
- Chronic renal changes exhibiting subnormal right kidney size and suspect mild left kidney compensatory hypertrophy, left kidney medullary mineral
- Mild urinary bladder sediment

## INTERPRETED BY

R. McKenzie Daniel,  
DVM, DABVP  
(Canine and Feline)

## IMAGING PERFORMED BY

Amanda Crook

## HOSPITAL NAME

Rivers Edge Pet  
Medical Center

## REFERRING VET

Dr Bridget Hayes

## INVOICE

25040

## DATE

06/08/2026

## INTERPRETATION OF THE FINDINGS & FURTHER RECOMMENDATIONS

A GI panel to include PLI/TLI/Cobalamin/Folate is recommended. Assuming normal clotting status and using a 25g needle, a splenic, accessible lymph node +/- hepatic FNA for screening cytology is warranted for assessment of occult disease as a contributing factor to the weight loss.

No overt evidence of renal neoplastic criteria. Correlation with full urinary workup including C/S if inflammatory sediment or UPC level if non-inflammatory proteinuria is recommended. Protein electrophoresis could be considered if persistent or progressive hyperglobulinemia.



**PATIENT**

Sebastian Robertson

**SPECIES**

Feline

**BREED**

DSH

**SEX**

MN

**AGE**

7yr

**WEIGHT**

10.42lb

**INTERPRETED BY**

R. McKenzie Daniel,  
DVM, DABVP  
(Canine and Feline)

**IMAGING PERFORMED BY**

Amanda Crook

**HOSPITAL NAME**

Rivers Edge Pet  
Medical Center

**REFERRING VET**

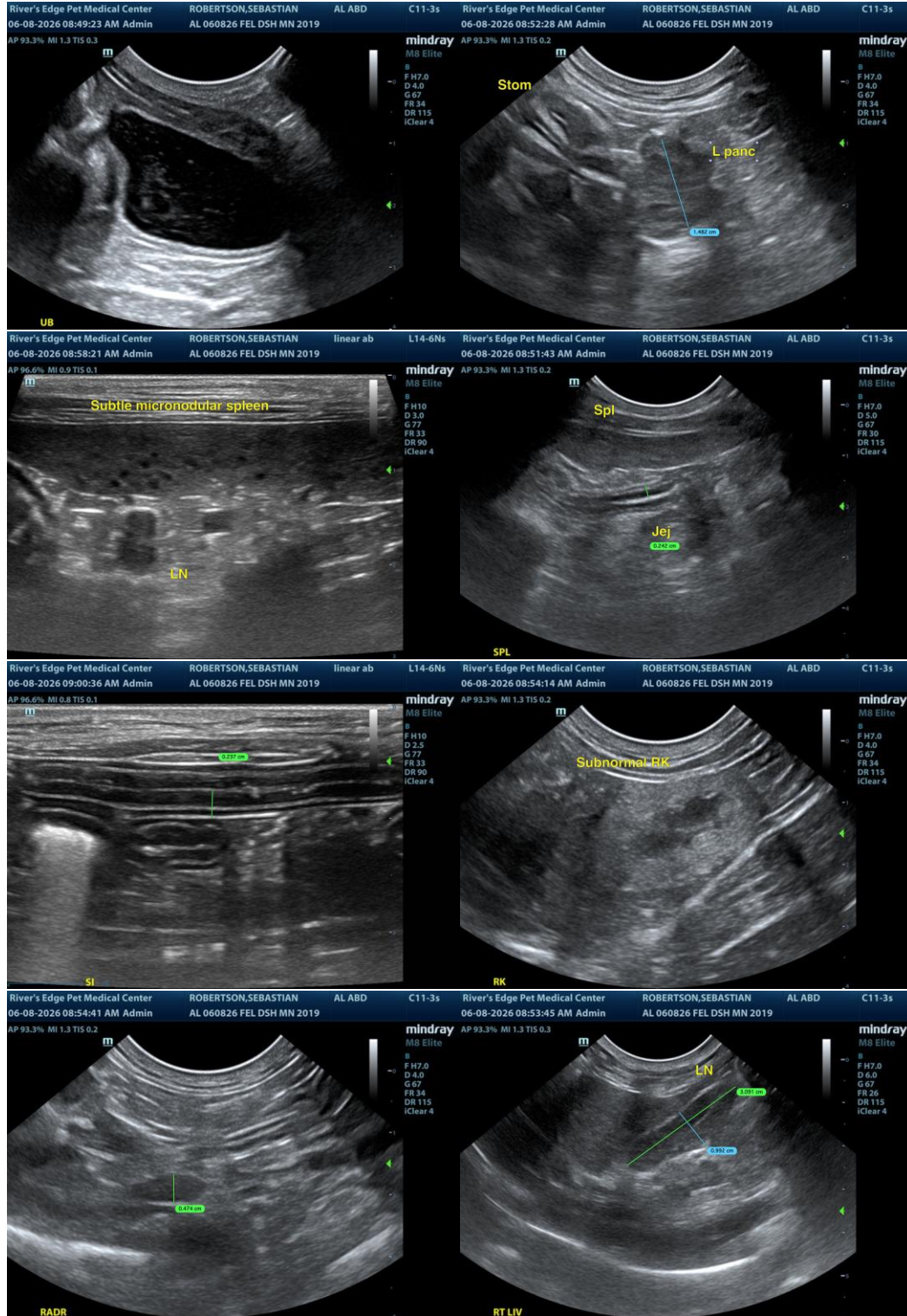
Dr Bridget Hayes

**INVOICE**

25040

**DATE**

06/08/2026





**PATIENT**

Sebastian Robertson

**SPECIES**

Feline

**BREED**

DSH

**SEX**

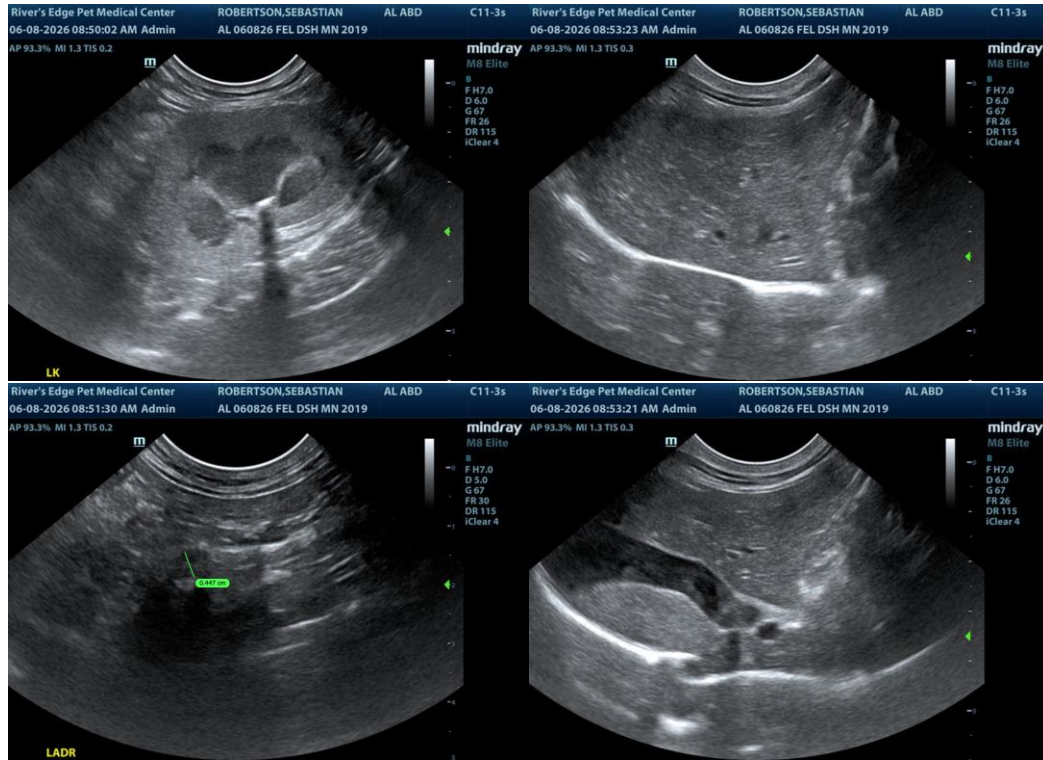
MN

**AGE**

7yr

**WEIGHT**

10.42lb



**INTERPRETED BY**

R. McKenzie Daniel,  
DVM, DABVP  
(Canine and Feline)

**IMAGING PERFORMED BY**

Amanda Crook

**HOSPITAL NAME**

Rivers Edge Pet  
Medical Center

**REFERRING VET**

Dr Bridget Hayes

**INVOICE**  
25040

**DATE**  
06/08/2026

The information and recommendations provided are based on the images presented by the referring veterinarian/sonographer. No evaluation can be communicated regarding pathology that was not visible in the image/video clips provided.

Thank you for this referral. If the clinical or image interpretation does not parallel your findings or if I can be of any further assistance, please contact me.

R. McKenzie Daniel, DVM, DABVP (Canine/Feline Practice)  
[info@sonopath.com](mailto:info@sonopath.com)